



Intramuscular Gluteal Implants: 15 Years' Experience

Rafael Vergara, MD; and Hugo Amezcua, MD

Dr. Vergara and Dr. Amezcua are in private practice in Guadalajara, Jalisco, Mexico.
They both are members of the Mexican Association of Plastic, Aesthetic and Reconstructive Surgery.

Background: *The history of gluteoplasty augmentation includes only a few reported clinical series.*

Objective: *We report our experience in performing gluteal augmentation using an intramuscular technique in 160 cases over 15 years. We also establish guidelines for performing this procedure.*

Methods: *All patients were women, ranging in age from 18 to 65 years, who underwent intramuscular gluteoplasty between June 1986 and September 2000. Of these patients, 104 (65%) received textured silicone gel implants and 56 (35%) received textured silicone elastomer implants. Thirty patients (18.7%) received 250-cc implants, 100 (62.5%) received 300-cc implants, and 30 (18.5%) received 350-cc implants.*

Results: *Satisfactory aesthetic results were obtained in 144 of 160 patients (90%). Complications presented in 16 patients (10%), including seroma in 7 patients (4%), asymmetry in 4 patients (2.66%), capsular contracture in 3 patients (2%), overcorrection in 1 patient (0.66%), and rupture of the implant in 1 patient (0.66%).*

Conclusions: *Intramuscular gluteal augmentation offers long-term, predictable, and pleasing aesthetic results with a low incidence of major complications. (Aesthetic Surg J 2003;23:86-91.)*

Gluteal augmentation is an evolving procedure. Among the variables undergoing modification are the optimal placement of the implant, the composition and design of the prosthesis, and the best technique for achieving aesthetic results that are in harmony with the anatomy and structure of the gluteal region. Perhaps this is why only a few clinical series of gluteal augmentation procedures have been reported.

The history of gluteal augmentation began in 1965, when Bartels¹ used a mammary prosthesis in the gluteal region. Cocke² in 1973, Douglas³ in 1975, and Buchuk⁴ reported their experiences with gluteal augmentation. In 1977,⁵ Gonzalez Ulloa presented a revision of the correction of hypoplastic gluteals. He reported on 10 years' experience with gluteal augmentation in 1991.⁶ Robles⁸ in 1984 reported his experience with submuscular gluteal augmentation using mammary implants in nine cases. Vergara⁹ reported on gluteal augmentation using an intramuscular technique in 1996.

In this paper, we present our experience with the intramuscular technique of gluteal augmentation in 160 procedures performed over 15 years. In our opinion, our results confirm that this technique offers predictable aesthetic results with a low incidence of major complica-

tions. In addition, we have outlined a selection process to achieve the best results.

Patients and Methods

We present a retrospective, observational, and descriptive study of gluteal augmentation procedures performed in 160 patients in a private practice between June 1986 and September 2000. The patients were all women, ranging in age from 18 to 65 years (median 31 years).

Preoperative indications for our patients included primary gluteoplasty in patients with good gluteal muscle tone and good skin; ptosis and gluteal flaccidity; secondary gluteoplasty; hypoplasia glutea; congenital gluteal deformity; gluteal asymmetry (posttraumatic, iatrogenic, sequelae). All patients received textured-surface intramuscular gluteal implants; the decision to use silicone gel implants or solid silicone elastomer implants depended on the patient's muscle tone as determined by clinical evaluation of gluteal soft tissues. Of the 160 patients, 104 (65%) received silicone gel implants and 56 (35%) received silicone elastomer implants. Thirty patients (18.7%) received 250-cc implants, 100 (62.5%) received 300-cc implants, and 30 received 350-cc implants.

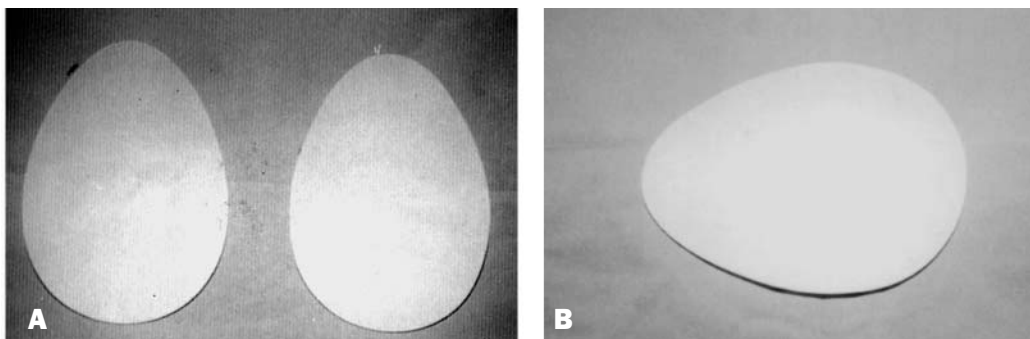


Figure 1. A, B, *cohesive silicone gel implants.*

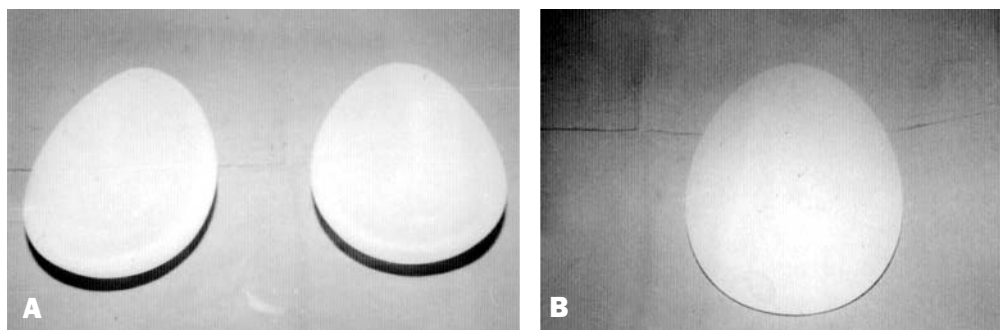


Figure 2. A, B, *solid silicone elastomer implants.*

Solid silicone elastomer implants were used in cases in which increasing gluteal tone was necessary, including patients with ptosis and gluteal flaccidity, congenital or acquired gluteal deformities, or gluteal asymmetry (Figure 1), as well as in patients undergoing secondary gluteal augmentation. Silicone gel implants were used in cases in which gluteal augmentation but not increased gluteal tone was necessary — for instance, in patients with good gluteal muscle tone who sought primary gluteal augmentation (Figure 2).

All patients were photographed before and after surgery and underwent periodic clinical follow-up.

Surgical Technique

Preoperative marking was performed with the patient in both the standing and seated positions. To delineate the gluteal region and the placement site for the implant, the following markings were made (Figure 3). The upper limit (iliac crest) and lower limit (infragluteal fold) of the surgical area were delineated. The infragluteal fold was marked as the lower limit to ensure preservation of the structure and thus avoid ptosis of the gluteal mass and implant displacement. The area between the iliac crest and the infragluteal fold was divided into 3 equal parts, with the upper third left undisturbed, the middle third

marked for placement of the implant, and the lower third left undisturbed with respect to the support zone (the ischium) that supports the weight of the body when sitting. The lateral position of the implants was marked as 4 cm from the intergluteal sulcus on both sides.

The anus was isolated by a compress sutured to the skin (Figure 3, D). A 6- to 7-cm incision was made in the intergluteal sulcus, 4 cm above the anus or 2 cm above mucocutaneous union. The incision was deepened through the fat layer to the level of the presacral fascia. The dissection was then continued superficially to the fascia for approximately 3 to 4 cm until the gluteus maximus muscle was reached.

A 6- to 7-cm incision at the aponeurosis of the gluteus maximus muscle was made and intramuscular dissection was performed with a gluteal dissector to create a cavity (virtual space) between the fasciculi of the gluteus maximus muscle (intramuscular space). This space was developed in the middle of the muscle mass of the gluteus maximus, at a depth of 2 to 3 cm into the muscle mass itself, so that the muscular fibers above, below, and behind the implant could be used to completely cover it. The lower pole (the thicker aspect of the implant) was folded and introduced through the incision in the intramuscular space, followed by the upper pole. A suction

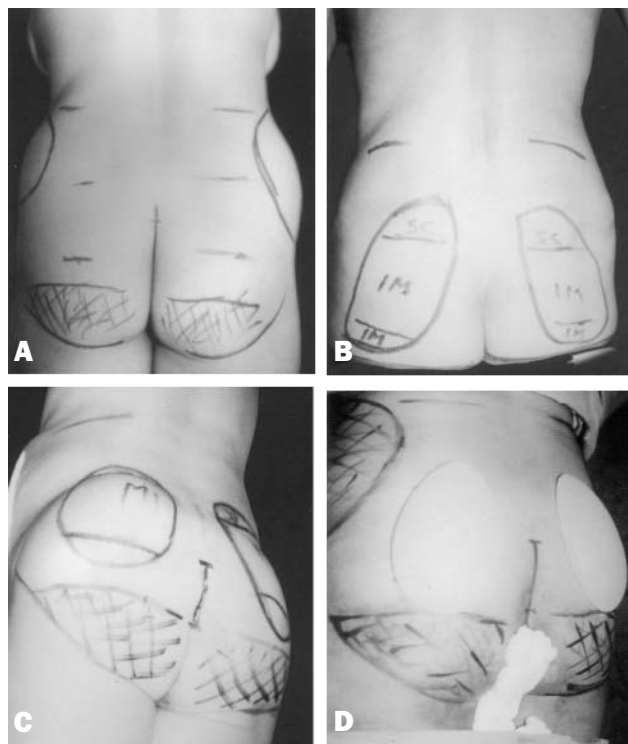


Figure 3. A-D, Preoperative markings. Implants are placed in the intramuscular (IM, MI) space.

drain was placed in the intramuscular space, along the implant. Suturing with nonabsorbable 3-0 and 4-0 nylon sutures was performed by planes through the muscle layer, fat layer, and dermis to the presacral fascia to fix the intergluteal sulcus and skin in place.

Postoperative Treatment

To immobilize the gluteal region surgical area and decrease swelling, an elastic dressing (Tenso, Ningbo, China) was used for 7 days after surgery, followed by the use of an elastic dressing and a Lycra panty for 3 weeks. Prophylactic antibiotic therapy with third-generation cephalosporins was administered both during and after surgery (ceftriaxone, 1 g IV 30 minutes before surgery and 1 g IV every 12 hours for 24 to 48 hours after surgery, followed by oral cefadroxil, 1 g/day for 5 days). Antiinflammatory agents administered included hydrocortisone (1 g IV during surgery, 500 mg IV every 12 hours after surgery for 24 to 48 hours) and then oral celecoxib (200 mg every 12 hours for 7 days). Patients also received ketorolac as an analgesic, 60 mg IV immediately after surgery and 30 mg IV every 6 hours for 24 to 48 hours, followed by 10 mg orally every 6 to 8 hours for 2 days or longer, if necessary. The patient's bed, on the day of

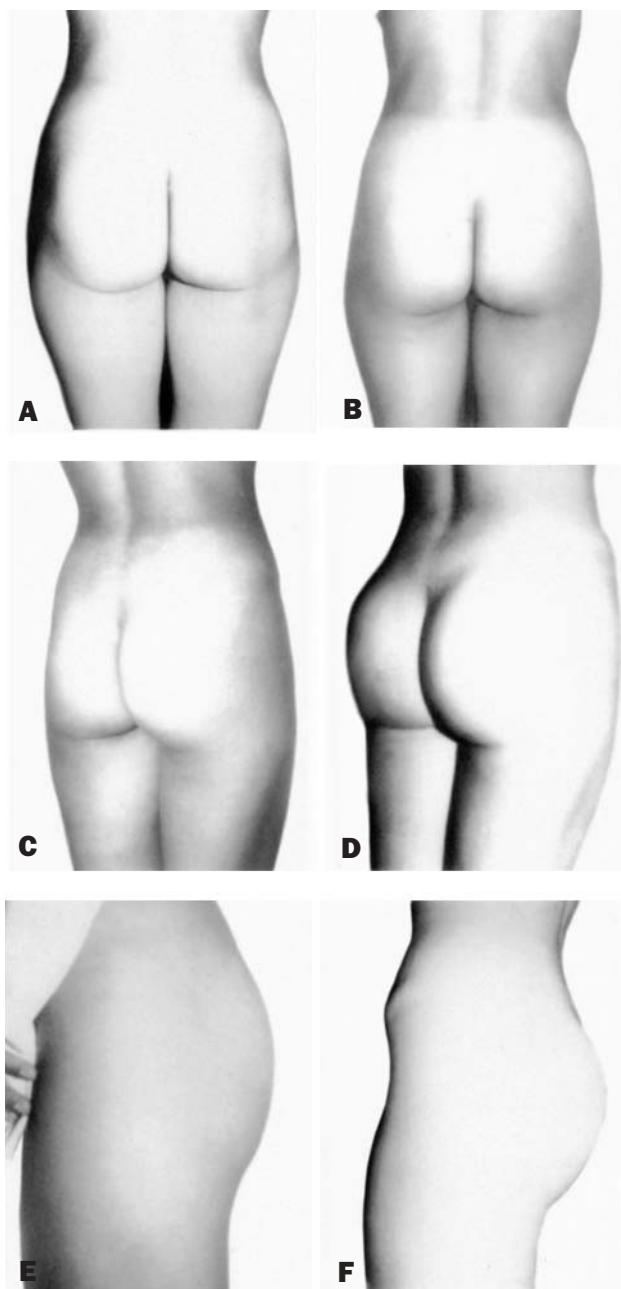


Figure 4. A, C, E, Preoperative views of a 23-year-old woman. **B, D, F,** Postoperative views 2 years after primary gluteal augmentation with 250-cc cohesive silicone gel implants.

surgery and for 2 weeks after surgery, was set in the supine decubitus position and, later, the decubitus position. Patients were able to sit down on the day of surgery and were allowed to exercise 1 month after surgery. Conventional ultrasound treatments were administered beginning with the third postoperative week to treat pain and edema and to prevent capsular contracture.

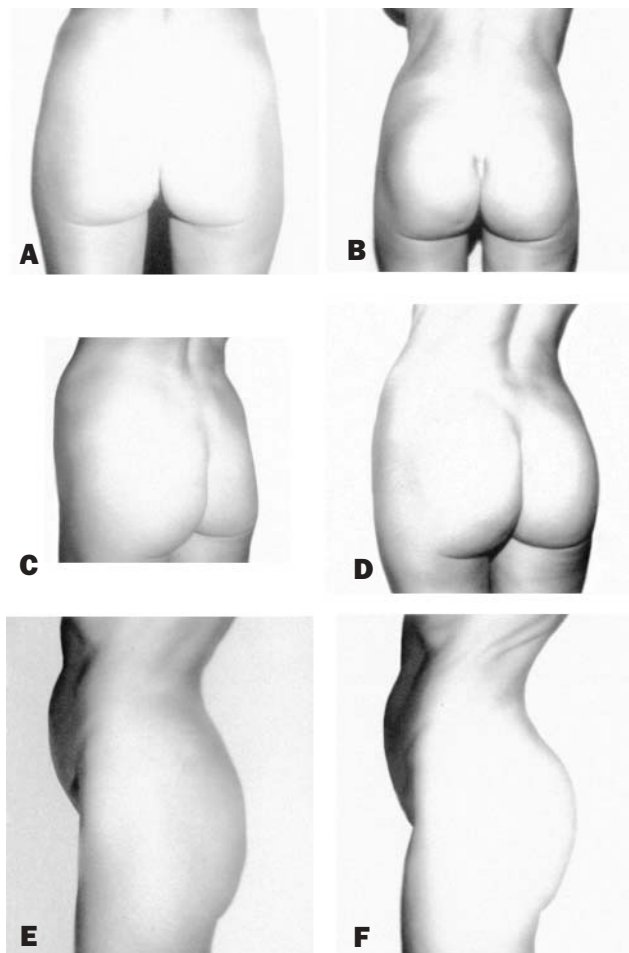


Figure 5. A, C, E, Preoperative views of a 28-year-old woman with gluteal flaccidity. **B, D, F,** Postoperative views 1 year after primary gluteal augmentation with 350-cc solid silicone elastomer implants.

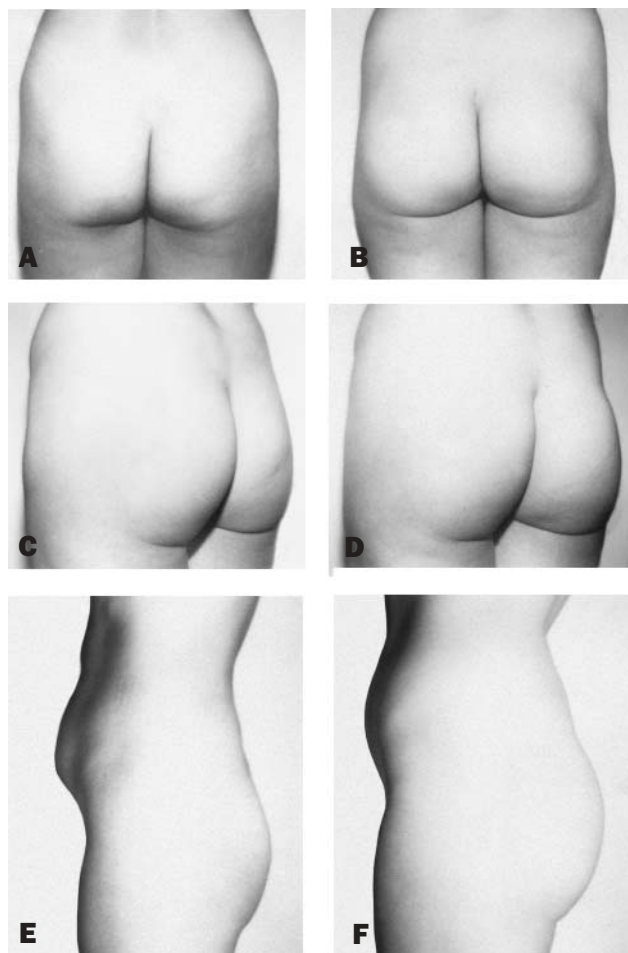


Figure 6. A, C, E, Preoperative views of a 21-year-old woman. **B, D, F,** Postoperative views 15 years after primary gluteal augmentation with 300-cc silicone gel implants.

Results

We obtained satisfactory aesthetic results without complications in 144 of 160 patients (90%) (Figures 4 to 6). Complications occurred in 16 of 160 patients (10%), as follows: seroma in 7 patients (4%), asymmetry in 4 patients (2.66%), capsular contracture in 3 patients (2%), overcorrection in 1 patient (0.66%), and rupture of the implant in 1 patient (0.66%). There were no instances of damage to the sciatic nerve, which has been reported as a possible complication of implantation involving the subgluteal technique.⁸ There were also no infections in our series.

Two cases of seroma resolved after replacement of the suction drain and additional local irrigation with hydrocortisone. One case resolved spontaneously. Three cases resolved after drainage by aspiration and additional irrigation with hydrocortisone. One case of chronic seroma

after implantation of gel implants that failed to respond to other treatments resolved when the implants were removed and replaced with silicone elastomer implants (Figures 7 and 8).

In 2 cases of asymmetry, the implants were too cranial; in another 2 cases, lateral displacement occurred after surgery. All 4 cases were successfully treated with surgical repositioning to correct the placement of the implant (Figure 9).

Three cases of Baker II capsular contracture resolved after 10 to 15 sessions of treatment with conventional ultrasound.

In 1 case of overcorrection, the patient decided to exchange her 350-cc implants for a smaller size a year after the initial surgery (Figure 10).

A 300-cc silicone gel prosthesis ruptured 6 years after it was implanted. The implant was removed, the cavity

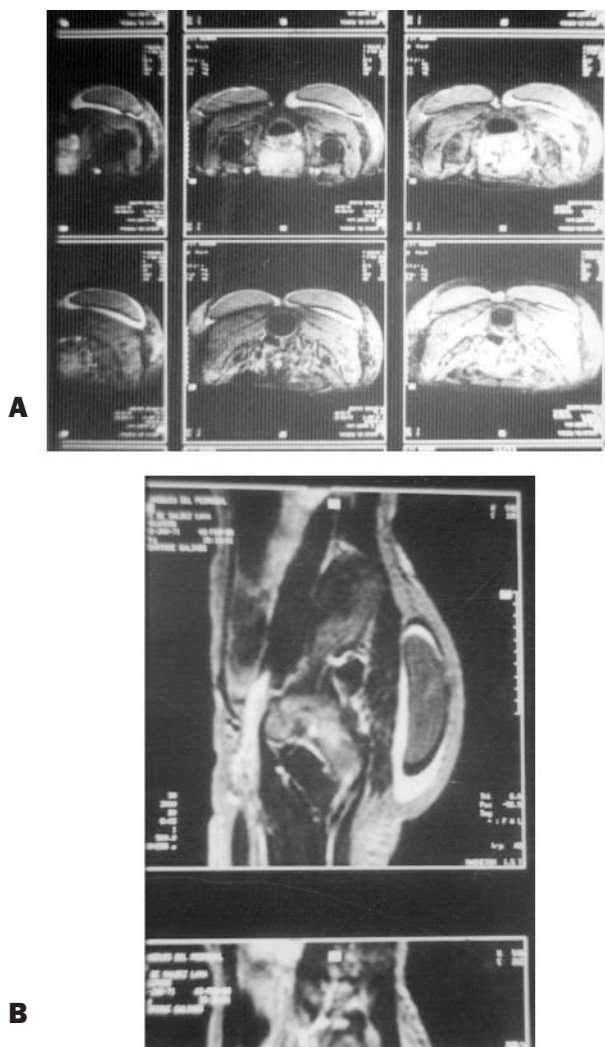


Figure 7. A,B Magnetic resonance imaging scans of a 29-year-old patient with seroma 2 years after placement of 350-cc silicone cohesive gel implants.

washed and cleaned, and a new textured silicone elastomer implant placed.

Discussion

Through the experience acquired during 15 years and 160 cases of gluteoplasty augmentation with gluteal implants, we recommend the following norms:

- (1) Use of the intergluteal fold incision. Do not use an approach through an incision in the infragluteal fold.
- (2) Placement of the implant in the intramuscular space (the virtual space) located between the fasciculi of the gluteus maximus muscle, taking care to leave at least 2 cm of the muscle fiber above the implant without reaching the submuscular space.
- (3) Use of oval cohesive gel or solid silicone elastomer

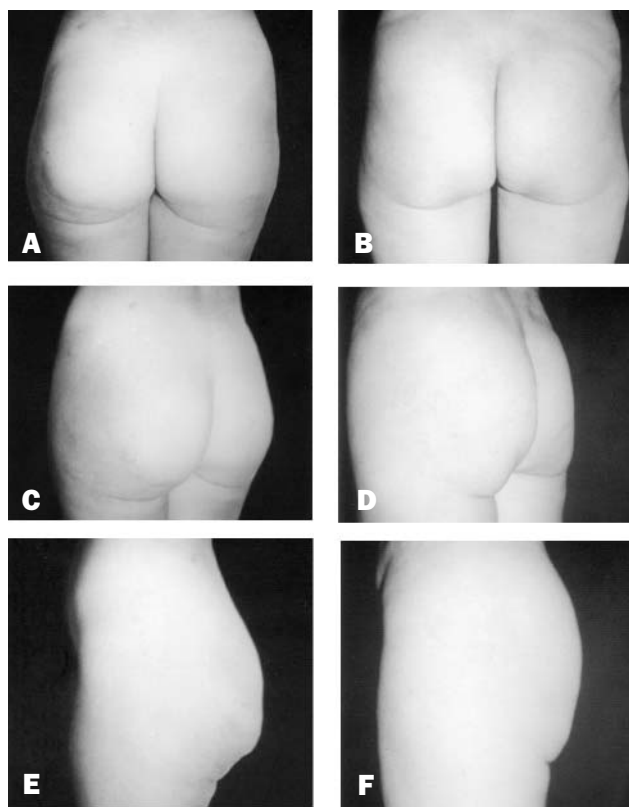


Figure 8. A, C, E Preoperative views of a 29-year-old woman with chronic seroma 2 years after primary gluteal augmentation with 350-cc silicone gel implants. **B, D, F**, Postoperative views 1 year after gel implants were removed and replaced with 350-cc silicone elastomer implants.

implants with a textured surface that are specifically designed for the gluteal area for patients with the described indications. Do not use mammary implants of any kind in the gluteal region.

(4) Placement of a suction drain for one week or until there is less than 50 mL of serohematic exudate.

(5) Use of conventional ultrasound therapy for 10 sessions, beginning with the 3rd postoperative week.

In all cases, use a special oval or almond-shaped prosthesis specifically designed for the gluteal zone. We consider the form of the prosthesis fundamental in achieving aesthetic augmentation and contour, even though the implants themselves are deeply placed.

The best results in gluteoplasty augmentation are achieved when the implants are placed in the intramuscular space because they can be covered with a musculocutaneous flap that maintains the implant's position and creates aesthetically pleasing harmonious, soft contours without irregularities. By contrast, implantation in the subcutaneous space is associated with complications, such as seromas, capsular contracture, visible implant

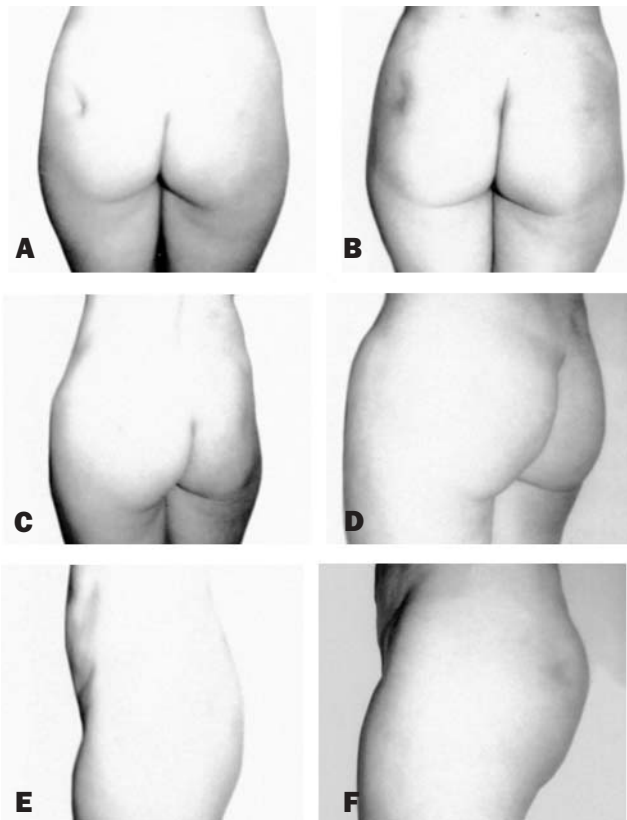


Figure 9. A, C, E, Preoperative views of a 34-year-old woman with gluteal asymmetry. **B, D, F,** Postoperative views 6 months after placement of 350-cc silicone elastomer implants.

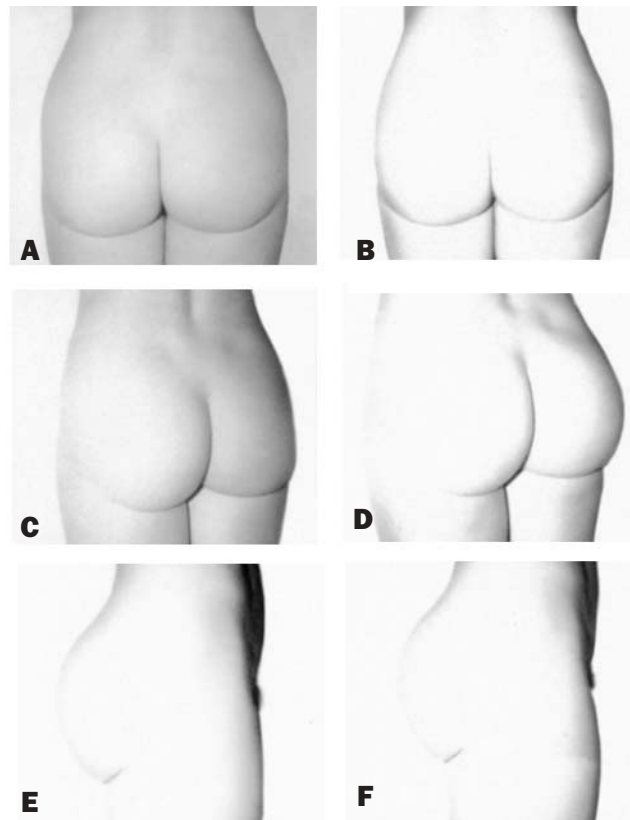


Figure 10. A, C, E, Preoperative views of a 24-year-old woman. **B, D, and F,** Postoperative views showing overcorrection 1 year after gluteal augmentation with 350-cc silicone gel implants. The patient decided to exchange the implants for a smaller size.

edges, and displacement of the implants.⁶ The submuscular space (Robles space) also presents difficulties because of its proximity to the sciatic nerve and the consequent possibility of damage to the nerve and because it permits the placement of small implants in only the highest positions.⁸

Conclusion

Intramuscular gluteoplasty augmentation with gluteal implants offers the best predictable long-term aesthetically pleasing results with no irregularities and only a low incidence of major complications.

References

1. Bartels RJ, O'Malley JE, Douglas WM. An unusual use of the Cronin breast prosthesis. *Plast Reconstr Surg* 1969;44:500.
2. Cocke WM, Ricketson G. Gluteal augmentation. *Plast Reconstr Surg* 1973;52:93.
3. Douglas WM, Bartels RJ, Baker JL. An experience in aesthetic buttocks augmentation. *Clin Plastic Surg* 1975;2:471.
4. Buchuk L. Gluteoplastia de aumento. *Cir Plast Iberolatinoamericana* 1980;6:29.

5. Gonzalez Ulloa M. A review of the present status of the correction for sad buttocks. IV Congress, *International Society of Aesthetic Plastic Surgery*. Mexico City, April 1977.
6. Gonzalez Ulloa M. Gluteoplasty: a ten-year report. *Aesth Plast Surg* 1991;5:85-91.
7. Gras Artero M. Asimetría glútea: corrección mediante injerto dermogasoaponeurotico de nalga contraria. *Rev Esp Cir Plast* 1974;7:185.
8. Robles JM, Tagliapietra JC, Grandi MA. Glúteoplastia de aumento: implantes submusculares. *Cir Plast Iberolatinoamericana* 1984;10:4.
9. Vergara R, Marcos M. Intramuscular gluteal implants. *Aesthetic Plast Surg* 1996;20:259-262.

Accepted October 25, 2002.

Reprint requests: Rafael Vergara, MD, Reforma 2837, 2nd Floor, Guadalajara, Jalisco CP 44620, Mexico.

Copyright © 2003 by The American Society for Aesthetic Plastic Surgery, Inc. 1090-820X/2003/\$30.00 + 0
doi:10.1067/maj.2003.17